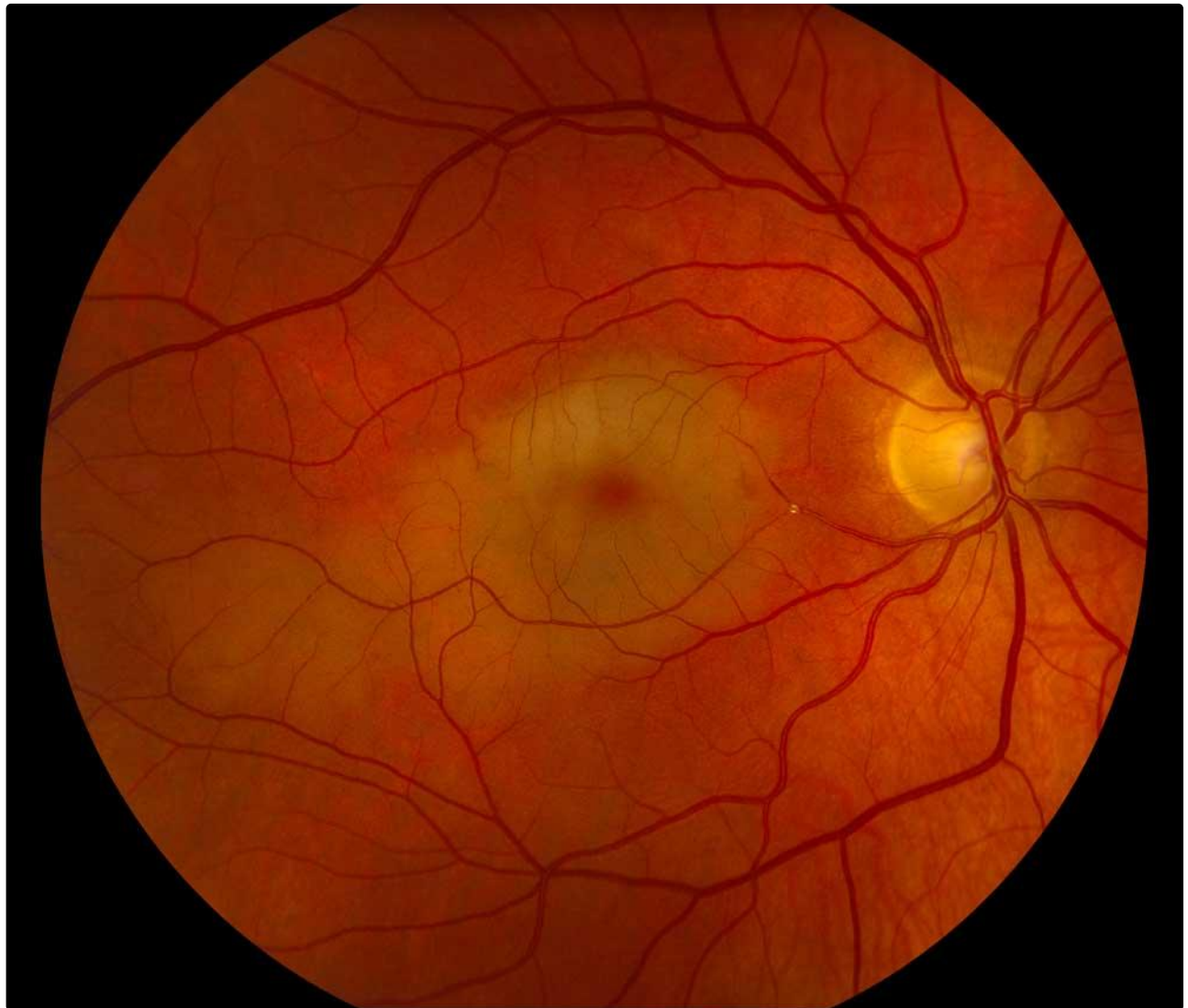


Hollenhorst plaque with branch retinal artery occlusion causing a cherry red spot

Category(ies): Retina, Vitreous

Contributor: [Matt Ward, MD](#)

Cherry red spots classically occur after CENTRAL retinal artery occlusion (CRAO). The cherry red spot occurs because the choroidal and retinal circulation is separate. The richly vascularized sub-foveal choriocapillaris remains perfused after CRAO, but the surrounding retina becomes opaque due to edema as the tissue becomes ischemic.



This was an interesting case in which a cholesterol (Hollenhorst) plaque became lodged in an inferior branch of the central retinal artery that perfused both the superior and inferior macula. Unfortunately for this patient this resulted in significant central vision loss.

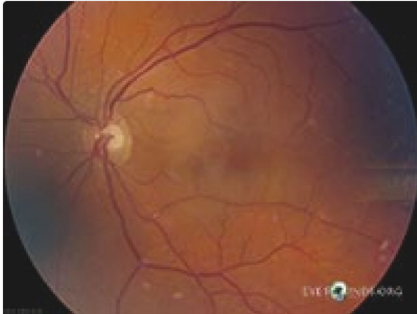Image Permissions:



Ophthalmic Atlas Images by EyeRounds.org, The University of Iowa are licensed under a [Creative Commons Attribution-NonCommercial-NoDerivs 3.0 Unported License](https://creativecommons.org/licenses/by-nc-nd/3.0/).



Related Articles



[Related Atlas Entry: Hollenhorst plaque in Branch Retinal Artery Occlusion \(BRAO\)](#)

Address

University of Iowa
Roy J. and Lucille A. Carver College
of Medicine
Department of Ophthalmology and
Visual Sciences
200 Hawkins Drive
Iowa City, IA 52242

[Support Us](#)

Legal

Copyright © 2019 The University of
Iowa. All Rights Reserved
[Report an issue with this page](#)
[Web Privacy Policy](#) |
[Nondiscrimination Statement](#)

Related Links

[Cataract Surgery for Greenhorns](#)
[EyeTransillumination](#)
[Gonioscopy.org](#)
[Iowa Glaucoma Curriculum](#)
[Iowa Wet Lab](#)
[Patient Information](#)
[Stone Rounds](#)
[The Best Hits Bookshelf](#)

EyeRounds Social Media

Follow



Receive notification of new cases,
[sign up here](#)
[Contact Us](#)
[Submit a Suggestion](#)